

# Risk of Neurological Decompression Sickness in the Diver With a Right-to-Left Shunt: Literature Review and Meta-Analysis

Olivier Lairez, MD,\* Maxime Cournot, MD,\*† Vincent Minville, MD,‡ Jérôme Roncalli, MD, PhD,\* Julien Austruy, MD,\* Meyer Elbaz, MD,\* Michel Galinier, MD, PhD,\* and Didier Carrié, MD, PhD\*

## INTRODUCTION

**Objective:** Literature review and meta-analysis to review the evidence of relationship between the presence of right-to-left shunts (RLSs) and the occurrence of neurological decompression sickness (DCS) in divers.

**Data Sources:** MEDLINE, Google Scholar, and Health Technology Assessment databases.

**Study Selection:** Five case-control studies in which the prevalence of a RLS in a group of divers with neurological DCS was compared with that of a group of divers with no history of DCS, 3 cross-transversal studies in which the prevalence of RLS was measured in divers with neurological DCS, and 4 cross-transversal studies in which the prevalence of RLS was measured in divers with no history of DCS were reviewed.

**Data Extraction:** Only case-control studies were retained for meta-analysis.

**Data Synthesis:** This meta-analysis gathers 5 studies and 654 divers. The combined odds ratio of neurological DCS in divers with RLS was 4.23 (3.05-5.87). The meta-analysis including only large RLS found a combined odds ratio of 6.49 (4.34-9.71).

**Conclusions:** Because of a low incidence of neurological DCS, increase in absolute risk of neurological DCS due to RLS is probably small. Thus, in recreational diving, the systematic screening of RLS seems unnecessary. In professional divers, because of a chronic exposition and unknown consequences of cerebral asymptomatic lesions, these results raise again the benefit of the transcranial Doppler in the screening and quantification of the RLS, independently of their location.

**Key Words:** diving, decompression illness, patent foramen ovale, right to left shunt, transcranial Doppler

(*Clin J Sport Med* 2009;19:231-235)

Submitted for publication March 16, 2008; accepted December 18, 2008. From the \*Department of Cardiology; †Epidemiology; and ‡Anesthesiology, CHU Rangueil, Toulouse, France.

The authors state that they have no financial interest in the products mentioned within this article.

Reprints: Olivier Lairez, MD, Department of Cardiology, University Hospital of Toulouse, Toulouse 31000, France (e-mail: lairez@gmail.com).

Copyright © 2009 by Lippincott Williams & Wilkins

Neurological decompression sickness (DCS) is one of the principal factors limiting the practice of both recreational and professional diving as it exposes the diver to functional and vital risks. DCS is caused by tissue ischemia from air embolism originating from the obstruction of arterial or venous blood flow. While diving, the bubble releasing arises during or after from a dive (decompression) by continued expansion of inert gases in the peripheral tissues saturated in the course of the dive.<sup>1-3</sup> DCS is manifested in 2 major forms: type 1 DCS involving only muscle and joint pain, fatigue, and/or skin symptoms and type 2 DCS that includes symptoms involving the central nervous system, respiratory system, or circulatory system.<sup>4</sup>

Right-to-left shunts (RLSs) have been reported since 1986 to increase the risk of type 2 DCS and particularly neurological DCS.<sup>5</sup> Nevertheless, there are still no recommendations for prevention, diagnosis, and management of the diver with an RLS.

The aim of our study was to quantify the association between the presence of an RLS in the diver with the occurrence of neurological DCS and to consider the diagnostic possibilities for these shunts and their consequences for the practice of diving.

## METHODS

### Data Abstraction

For this investigation, we referred to the MEDLINE (www.pubmed.gov), Google Scholar (www.scholar.google.com), and Health Technology Assessment (www.crd.york.ac.uk) databases, selecting articles using the MeSH key words *right to left shunt*, *interatrial shunt*, *patent foramen ovale*, and *persistent foramen ovale* combined with the key words *divers* and *diving*. To broaden the search, we used the “related articles” function. This strategy was complemented by a manual search of secondary sources from the bibliographic references of the initially selected articles.

For this study, we were interested in only neurological DCS including cerebral, spinal, and vestibulocochlear DCS. At the end of this search, only articles in English and French that met the following inclusion criteria were selected:

- Observational study comparing the prevalence of RLS in a group of divers with neurological DCS to that of a control group composed of divers with no history of DCS.

- Cross-sectional study calculating the prevalence of RLS in a group of divers with neurological DCS.
- Cross-sectional study calculating the prevalence of RLS in a group of divers with no history of DCS. The following were excluded from the analysis:
  - Studies of nondivers
  - Non-neurological DCS and asymptomatic DCS of diving, shown by cerebral imaging
  - Pulmonary and inner ear barotraumas
  - Experimental studies
  - Reviews of the literature
  - Case reports.

### Meta-Analysis

For reasons of homogeneity, only case-control studies comparing the prevalence of RLS in a group of divers with neurological DCS to that of a control group composed of divers with no history of DCS were retained for meta-analysis. The corresponding odds ratio and their confidence intervals were calculated for each study. The combined odds ratio was calculated using a fixed effects model with weighting by the inverse of the variance. The heterogeneity between studies was tested by the  $I^2$  statistic. The analyses were performed with Stata 9.0 (StataCorp LP, College Station, Texas).

## RESULTS

### Review of Available Data

In 1986, Wilmshurst et al<sup>5</sup> reported first the case of a paradoxical air embolus in a diver with an atrial septal defect. Since then, case reports have proliferated in the literature.

In 1989, Moon et al<sup>6</sup> reported the prevalence of a patent foramen ovale (PFO) to be 37% in a population of 30 divers who developed DCS, a figure that increased to 61% among the 18 most serious cases. This result is significantly greater than the 5% prevalence of PFO found using the same diagnostic technique in a control group composed of 176 nondiver subjects stemming from 2 previous studies.<sup>7,8</sup> Authors concluded that the presence of a PFO seems to be a risk factor for the development of DCS in divers.

At the end of our search, we were able to identify 5 case-control studies in which the prevalence of a RLS in divers with neurological DCS was compared with that of a group of divers without DCS,<sup>9-13</sup> 3 cross-transversal studies in which the prevalence of RLS was measured in divers with neurological DCS,<sup>14-16</sup> and 4 cross-transversal studies in which the prevalence of RLS was measured in divers with no history of DCS.<sup>17-20</sup>

The retrospective cohort study of Schwerzmann et al<sup>21</sup> was not retained because Torti et al<sup>15</sup> took his series again. The other works from Wilmshurst et al<sup>22-24</sup> were not retained because their population sample had already been published in previous articles retained here.<sup>9,13</sup> Currently, no prospective series exist that examine the relative risk of DCS for divers with this type of shunt. Among the 605 divers in the control groups, there were a total of 179 RLSs, or an incidence of 29.6%, that corresponded to the incidence of PFOs found in necroscopic series.<sup>25</sup> In 1998, Germonpre et al<sup>10</sup> found that the

risk was even more significant when the RLS through the PFO was high grade (significant flow of contrast,  $\geq 20$  bubbles, spontaneously or after Valsalva maneuver). Among the 527 divers in the control groups, the prevalence of a high-grade RLS is no more than 14.2%. The synthesis of this search is presented in Table 1.

### Meta-Analysis

Five case-control studies have reported 277 RLS of 654 subjects.<sup>9-13</sup> Among these 5 studies, the search for RLS was limited to the diagnosis of PFO by transthoracic echocardiography in 2 cases<sup>9,13</sup> and by transesophageal echocardiography in 2 cases.<sup>10,12</sup> In the last case, the presence of an RLS was confirmed by transcranial Doppler (TCD).<sup>11</sup>

The combined odds ratio of neurological DCS for the divers with RLSs was 4.23 (3.05-5.87). There was no significant heterogeneity among the studies ( $P$  heterogeneity = 0.34). These results are presented in Figure 1.

In these 5 studies, a quantitative approach for RLS was employed. For our study, the RLS was qualified as high grade in the case of a spontaneous shunt, apart from all sensitizing maneuvers, in 2 cases.<sup>9,12</sup> In the other 3 cases, the RLS was considered high grade in the case of large-scale passage of microbubbles or contrast through the shunt ( $>20$  microbubbles), independent of any sensitizing maneuvers.<sup>10,11,13</sup>

The meta-analysis performed upon only high-grade RLSs revealed a combined odds ratio of 6.49 (4.34-9.71). The heterogeneity between the studies was at the limit of significance ( $P$  heterogeneity = 0.07). The results are presented in Figure 2.

## DISCUSSION

This literature review of 5 controlled trials among some 654 participants suggests that divers with RLS are at higher risk of neurological DCS, with a combined odds ratio of 4.23 (3.05-5.87). The meta-analysis including only large RLS found a combined odds ratio of 6.49 (4.34-9.71).

In our study, the risk of neurological DCS increases with the size of the shunt. This result should lead to investigation based on the quantification of a functional entity rather than the search for an anatomic entity, while examining the degree of RLS. In accepting the concept that the venous bubble phenomenon is quasi-systemic during decompression,<sup>3,26</sup> it is clear that all RLSs will carry more risk that they will be permeable, thus permitting the massive arterializations of venous bubbles from tissue salting out upon decompression.<sup>27</sup> This would explain the increase of asymptomatic cerebral lesions in divers compared with nondivers found by Reul et al,<sup>28</sup> via the passage of microbubbles through the physiological RLS performed by the pulmonary capillary bed. According to the work of Knauth et al,<sup>19</sup> the presence of multiple asymptomatic cerebral lesions detected by magnetic resonance imaging (MRI) would be found almost exclusively in those divers with high-grade RLSs detected by TCD. On his part, Schwerzmann found 5 times more cerebral lesions in divers than in nondivers, with twice as many lesions in divers with PFOs than in divers without PFOs.<sup>21</sup> However, these results have to be moderated by the Koch et al<sup>20</sup> and Gerriets

**TABLE 1.** Review of Available Epidemiological Data on the Presence of an RLS or High-Grade RLS and the Occurrence of Neurological DCS

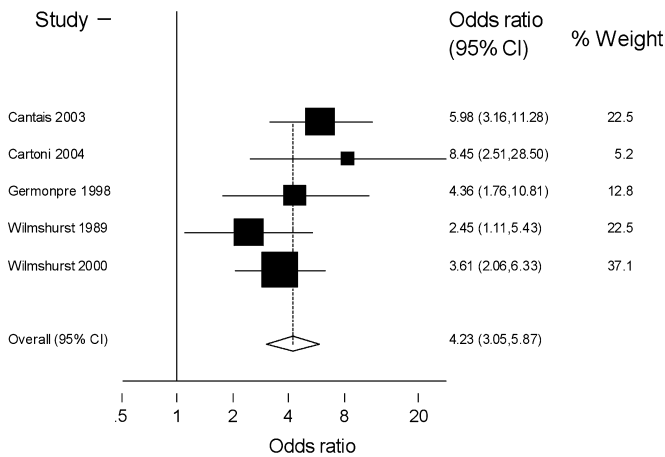
Studies	Population	Diagnosis Method	RLS, No. (%)	High-Grade RLS, No. (%)	
<b>Case-control Studies</b>					
Cartoni et al <sup>12</sup>	Neurological DCS (n = 30)	Professional divers	TEE	23 (76.7)	15 (50)
	Control (n = 25)	Professional divers	TEE	7 (28)	1 (4)
Cantais et al <sup>11</sup>	Neurological DCS (n = 86)	Divers	TCD	57 (66.3)	47 (54.6)
	Control (n = 101)	Divers	TCD	25 (24.8)	12 (11.9)
Wilmshurst and Bryson <sup>13</sup>	Neurological DCS (n = 100)	Recreational (n = 91) and professional (n = 9) divers	TTE	58 (58)	51 (51)
	Control (n = 123)	Divers	TTE	34 (27.6)	9 (7.3)
Germonpre et al <sup>10</sup>	Neurological DCS (n = 37)	Divers	TEE	22 (59.5)	19 (51.3)
	Control (n = 36)	Divers	TEE	13 (36.1)	9 (25)
Wilmshurst et al <sup>9</sup>	Neurological DCS (n = 53)	Recreational (n = 59) and professional (n = 2) divers	TTE	23 (43)	14 (26)
	Control (n = 63)	Recreational divers	TTE	15 (24)	8 (12.7)
<b>Cross-sectional Studies</b>					
Klingmann et al <sup>14</sup>	Neurological DCS (n = 18)	Divers	TCD	x	15 (83.3)
	Control (n = 0)	x	x	x	x
Torti et al <sup>15</sup>	Neurological DCS (n = 28)	Recreational divers	TEE	18 (64.3)	x
	Control (n = 0)	x	x	x	x
Koch et al <sup>20</sup>	Neurological DCS (n = 0)	x	x	x	x
	Control (n = 50)	Divers	TEE and TCD	18 (36)	12 (24)
Gerriets et al <sup>17</sup>	Neurological DCS (n = 0)	x	x	x	x
	Control (n = 42)	Recreational divers	TCD	16 (38)	11 (26.2)
Klingmann et al <sup>16</sup>	Neurological DCS (n = 9)	Divers	TCD	9 (100)	9 (100)
	Control (n = 0)	x	x	x	x
Cross et al <sup>18</sup>	Neurological DCS (n = 0)	x	x	x	x
	Control (n = 78)	Recreational divers	TEE	26 (33.3)	x
Knauth et al <sup>19</sup>	Neurological DCS (n = 0)	x	x	x	x
	Control (n = 87)	Recreational divers	TCD	25 (28.7)	13 (14.9)

TCD, transcranial Doppler; TEE, transesophageal echocardiography; TTE, transthoracic echocardiography; x, not reported.

et al<sup>17</sup> results, which do not draw the same conclusion. Effectively, they did not find any association between brain lesions and the presence of an RLS in divers. Gerriets et al<sup>17</sup> showed that the presence of postdive arterial gas emboli is common after routine dives in divers with an RLS and is not necessarily related to the development of brain lesions on MRI. However, in that study, divers were young ( $35.7 \pm 7.9$  and  $32.2 \pm 7.5$  years). Tetzlaff et al<sup>29</sup> showed that MRI brain lesions are more frequent in elderly divers and correlated with decrease of mental flexibility and visual tracking performance in comparison with healthy commercial employees. The long-term clinical consequences of diving with the presence of a RLS are still unknown. In addition, even if we know that the prevalence of the PFO decreases with the age, its size goes by increasing.<sup>25</sup> This observation would be particularly true with the divers, as demonstrated by Germonpre who studied the evolution of the prevalence and the size of the PFO on a series of 40 divers 6–8 years after a first evaluation by transesophageal echocardiography.<sup>30</sup> This study showed

a significant evolution of the PFO, with an increase in its permeability at 22.5% of the divers. These results could be explained by the practice of the Valsalva maneuver during the descent that favors the reopening of the PFO.

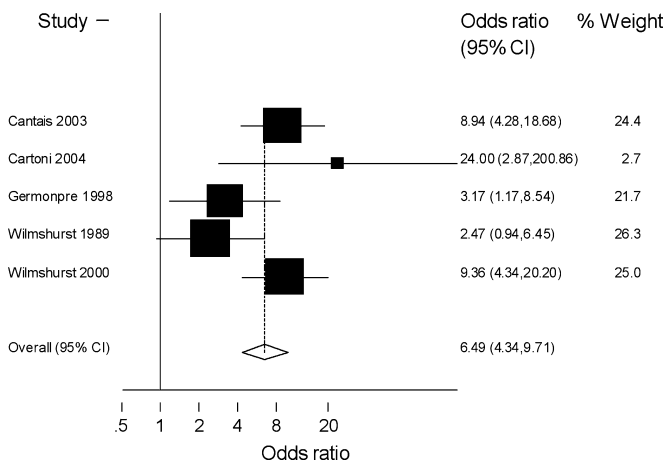
However, all neurological DCS is not due to RLS, and all divers with RLS do not have neurological DCS. Effectively, statistically, at least a quarter of divers having neurological DCS have a RLS. DCS is due to bubbles forming during the ascent and not to the RLS. Thus, in agreement with our results, RLS may represent a susceptibility to neurological DCS but is not sufficient to induce neurological DCS.<sup>31</sup> Therefore, there must be other factors to produce neurological DCS, such as bubble load or other susceptibility factor probably involving body tissues. In its 2006 annual diving report, the Divers Alert Network reported an overall DCS incidence of 3.6 cases per 10,000 dives based on the contribution of over 8000 recreational divers representing more than 100 000 dives between 2004 and 2006.<sup>32</sup> The 2006 report described data from 1521 divers and 23 912 dives



**FIGURE 1.** Odds ratio of neurological DCS in subjects with RLS (case-control studies).

collected in 2004. It reported a type 2 DCS incidence of 1.25 cases per 10 000 dives and a neurological DCS incidence of 0.84 cases per 10 000 dives (dive fatalities not included). The increase in absolute risk of neurological DCS due to RLS cannot be calculated with an odds ratio but seems to be small.

In primary prevention, the screening of shallow water recreational divers is probably unnecessary. Recreational divers should be informed of the risk of RLS in one-quarter of cases, as well as of the potential consequences and diagnostic possibilities.<sup>25</sup> In professional diving, however, the presence of a RLS exposes divers to a double risk: in the short term, represented by neurological DCS, and, in the long term, still not evaluated, represented by infraclinical cerebral lesions. Despite a low incidence of DCS,<sup>19</sup> but because of a high gas bubble load, military or commercial divers should undergo systematic screening of RLS with TCD. In cases of positive TCD, it should be recommended that professional divers with RLS reduce the venous bubble load by developing different decompression procedures (limiting speed of ascent), limiting bottom time or using appropriate oxygen-enriched breathing



**FIGURE 2.** Odds ratio of neurological DCS in subjects with high-grade RLS (case-control studies).

mixes, and adapting their practice to the level of risk in relation to the size of the shunt.

In secondary prevention, the question of transcatheter PFO closure arises. The effectiveness of transcatheter devices has not been proven; to date, no scientific evidence exists regarding the closure of a PFO to prevent DCS. As such, in secondary prevention, transcatheter devices in recreational divers should not be proposed. However, the question of percutaneous PFO closure in secondary prevention for professional divers remains. Braun et al<sup>33</sup> reported a series of 307 consecutive patients who underwent percutaneous closure of PFO because of paradoxical embolism. The implantation was successful in all patients. Complete PFO closure was achieved in 81%, 94%, and 96% after 6 months, 1 year, and 2 years of follow-up, respectively, and all patients with a residual shunt had a significant reduction of the shunt degree after device implantation. Two percent of patients had minor peri-interventional complications (transient ST-segment elevations and arteriovenous fistula), and 1% of patients had major peri-interventional complications including transient ischemic attack (completely resolved within 8 hours) and dislodgement of the device. There were no irreversible cerebral or peripheral ischemic events or death during the procedure. There were no deaths related to the intervention (median follow-up, 24 months; range, 3–51), but 2 patients required surgical removal of the device (device malalignment and device adherent thrombus). These results show that the interventional PFO closure is safe and is an effective technique with a high success rate. Moreover, 7 divers have benefited from the occluded devices to prevent recurrence of neurological DCS.<sup>34</sup> These divers were allowed to return to diving and experienced no further neurological decompression episodes; however, risk reduction is difficult to conclude in this instance and randomized clinical trials would be required to make such a determination. This type of study would be difficult to undertake, particularly from an ethical standpoint: it would be difficult to allow a subject with a history of DCS and RLS to dive knowing that he would be exposing himself to a major risk. Thus, in secondary prevention of professional divers, in the event of a positive TCD and in the absence of other causes of DCS, the workup should progress to transesophageal echocardiography in search of a PFO. In the case of a PFO, a percutaneous closure procedure could be considered. The closure effectiveness should be confirmed by a repeat TCD at a later date, after endothelialization of the prosthesis. The persistence of a RLS would be contraindicated to the diver continuing his professional activities.

**CONCLUSIONS**

The bullous phenomenon in the course of a dive occurs systematically at the time of decompression by venous release of inert gas by tissues saturated during compression. Usually, the pulmonary filter limits the arterialization of venous bubbles. In the diver with a RLS, whether cardiac or pulmonary, this filter loses its efficiency, causing a risk of cerebral lesions, both symptomatic and asymptomatic. The gravity of this risk corresponds directly to the magnitude of the shunt that can be detected and quantified by TCD. However, because of a low

incidence of neurological DCS, increase in absolute risk of neurological DCS due to RLS seems to be small.

In recreational diving, the systematic screening of RLS does not seem to be necessary. However, chronic exposition of divers to possible DCS and the unknown long-term consequences of cerebral asymptomatic lesions suggest that professional divers should undergo systematic screening of RLS for recommendations to reduce the venous bubble load. In secondary prevention, in the absence of other causes of DCS, the 4.23–6.49 odds ratio of neurological DCS of divers with RLS warrants future research examining PFOs and the need to consider a percutaneous closure procedure.

## REFERENCES

- Moon RE, Vann RD, Bennett PB. The physiology of decompression illness. *Sci Am*. 1995;273:70–77.
- Dukta A. Physiopathology of decompression sickness. In: Bove A, ed. *Bove and Davis' Diving Medicine*. 3rd ed. Philadelphia, PA: WB Saunders; 1997:159–171.
- Eckenhoff RG, Olstad CS, Carrod G. Human dose-response relationship for decompression and endogenous bubble formation. *J Appl Physiol*. 1990;69:914–918.
- Divers Alert Network. <http://dan.org/medical/dictionary.asp>.
- Wilmshurst PT, Ellis BG, Jenkins BS. Paradoxical gas embolism in a scuba diver with an atrial septal defect. *Br Med J (Clin Res Ed)*. 1986; 293:1277.
- Moon RE, Camporesi EM, Kisslo JA. Patent foramen ovale and decompression sickness in divers. *Lancet*. 1989;1:513–514.
- Lechat P, Mas JL, Lascault G, et al. Prevalence of patent foramen ovale in patients with stroke. *N Engl J Med*. 1988;318:1148–1152.
- Lynch JJ, Schuchard GH, Gross CM, et al. Prevalence of right-to-left atrial shunting in a healthy population: detection by Valsalva maneuver contrast echocardiography. *Am J Cardiol*. 1984;53:1478–1480.
- Wilmshurst PT, Byrne JC, Webb-Peploe MM. Relation between interatrial shunts and decompression sickness in divers. *Lancet*. 1989;2:1302–1306.
- Germonpre P, Dendale P, Unger P, et al. Patent foramen ovale and decompression sickness in sports divers. *J Appl Physiol*. 1998;84:1622–1626.
- Cantais E, Louge P, Suppini A, et al. Right-to-left shunt and risk of decompression illness with cochleovestibular and cerebral symptoms in divers: case control study in 101 consecutive dive accidents. *Crit Care Med*. 2003;31:84–88.
- Cartoni D, De Castro S, Valente G, et al. Identification of professional scuba divers with patent foramen ovale at risk for decompression illness. *Am J Cardiol*. 2004;94:270–273.
- Wilmshurst P, Bryson P. Relationship between the clinical features of neurological decompression illness and its causes. *Clin Sci (Lond)*. 2000; 99:65–75.
- Klingmann C, Praetorius M, Baumann I, et al. Barotrauma and decompression illness of the inner ear: 46 cases during treatment and follow-up. *Otol Neurotol*. 2007;28:447–454.
- Torti SR, Billinger M, Schwerzmann M, et al. Risk of decompression illness among 230 divers in relation to the presence and size of patent foramen ovale. *Eur Heart J*. 2004;25:1014–1020.
- Klingmann C, Benton PJ, Ringleb PA, et al. Embolic inner ear decompression illness: correlation with a right-to-left shunt. *Laryngoscope*. 2003;113:1356–1361.
- Gerriets T, Tetzlaff K, Hutzelmann A, et al. Association between right-to-left shunts and brain lesions in sport divers. *Aviat Space Environ Med*. 2003;74:1058–1060.
- Cross SJ, Evans SA, Thomson LF, et al. Safety of subaqua diving with a patent foramen ovale. *BMJ*. 1992;304:481–482.
- Knauth M, Ries S, Pohimann S, et al. Cohort study of multiple brain lesions in sport divers: role of a patent foramen ovale. *BMJ*. 1997;314: 701–705.
- Koch AE, Kampen J, Tetzlaff K, et al. Incidence of abnormal cerebral findings in the MRI of clinically healthy divers: role of a patent foramen ovale. *Undersea Hyperb Med*. 2004;31:261–268.
- Schwerzmann M, Seiler C, Lipp E, et al. Relation between directly detected patent foramen ovale and ischemic brain lesions in sport divers. *Ann Intern Med*. 2001;134:21–24.
- Wilmshurst PT, Treacher DF, Crowther A, et al. Effects of a patent foramen ovale on arterial saturation during exercise and on cardiovascular responses to deep breathing, Valsalva manoeuvre, and passive tilt: relation to history of decompression illness in divers. *Br Heart J*. 1994;71: 229–231.
- Wilmshurst P, Davidson C, O'Connell G, et al. Role of cardiorespiratory abnormalities, smoking and dive characteristics in the manifestations of neurological decompression illness. *Clin Sci (Lond)*. 1994;86:297–303.
- Wilmshurst PT, Pearson MJ, Walsh KP, et al. Relationship between right-to-left shunts and cutaneous decompression illness. *Clin Sci (Lond)*. 2001; 100:539–542.
- Hagen PT, Scholz DG, Edwards WD. Incidence and size of patent foramen ovale during the first 10 decades of life: an autopsy study of 965 normal hearts. *Mayo Clin Proc*. 1984;59:17–20.
- Dunford RG, Vann RD, Gerth WA, et al. The incidence of venous gas emboli in recreational diving. *Undersea Hyperb Med*. 2002;29:247–259.
- Ries S, Knauth M, Kern R, et al. Arterial gas embolism after decompression: correlation with right-to-left shunting. *Neurology*. 1999; 52:401–404.
- Reul J, Weis J, Jung A, et al. Central nervous system lesions and cervical disc herniations in amateur divers. *Lancet*. 1995;345:1403–1405.
- Tetzlaff K, Friege L, Hutzelmann A, et al. Magnetic resonance signal abnormalities and neuropsychological deficits in elderly compressed-air divers. *Eur Neurol*. 1999;42:194–199.
- Germonpre P, Hastir F, Dendale P, et al. Evidence for increasing patency of the foramen ovale in divers. *Am J Cardiol*. 2005;95:912–915.
- Glen SK, Georgiadis D, Grosset DG, et al. Transcranial Doppler ultrasound in commercial air divers: a field study including cases with right-to-left shunting. *Undersea Hyperb Med*. 1995;22:129–135.
- Vann RD, Freiburger JJ, Caruso JL, et al. Annual Diving Report: 2006 Edition. Divers Alert Network. <http://dan.org/medical/report/2006dandivingreport.pdf>.
- Braun M, Glicch V, Boscheri A, et al. Transcatheter closure of patent foramen ovale (PFO) in patients with paradoxical embolism. Periprocedural safety and mid-term follow-up results of three different device occluder systems. *Eur Heart J*. 2004;25:424–430.
- Walsh KP, Wilmshurst PT, Morrison WL. Transcatheter closure of patent foramen ovale using the Amplatzer septal occluder to prevent recurrence of neurological decompression illness in divers. *Heart*. 1999;81:257–261.